

CLINICAL IMAGES

Tension pneumocephalus



Sandeep Khanna ^{a,*}, Carlos Trombetta ^b, Kurt Ruetzler ^c, Maged Argalious ^a

^a Cleveland Clinic Foundation, Department of Cardiothoracic Anesthesiology, Department of General Anesthesiology and Department of Outcomes Research, Ohio, USA

^b Cleveland Clinic Foundation, Department of Cardiothoracic Anesthesiology and Department of General Anesthesiology, Ohio, USA

^c Cleveland Clinic Foundation, Department of General Anesthesiology and Department of Outcomes Research, Ohio, USA

Received 2 June 2023; accepted 16 July 2023
Available online 28 July 2023

Pneumocephalus, defined as presence of air or gas within the compartments of the cranial vault, can occur after neurosurgery and is typically benign. In contrast, tension pneumocephalus occurs when the pressure of the intracranial air collection exceeds atmospheric pressure, leading to brain compression. The resulting increase in intracranial pressure can precipitate nausea and vomiting, headaches, focal neurological deficits, seizures, altered mental status, and death. Consequently, tension pneumocephalus is a neurosurgical emergency.^{1,2} The accompanying images demonstrate this rare complication (Fig. 1: Panel A and B) and are from a patient who underwent craniotomy for meningioma resection. Delayed emergence and bilious vomiting prior to extubation prompted computed tomographic imaging revealing extensive pneumocephalus and the classic Mount Fuji sign in the axial section.³

Relief of the increased intracranial pressure can be achieved via needle aspiration, redo craniotomy, or drilling of burr holes. Hyperventilation, hypotension, and high airway pressures during mechanical ventilation in such patients can precipitate brain ischemia, infarction and/or herniation. High intrathoracic pressures decrease cerebral venous outflow, further raising intracranial pressure. Hyperventilation decreases cerebral blood flow while hypotension compromises cerebral perfusion pressure. When tension pneumocephalus is suspected, it is best to avoid nitrous oxide during anesthetic maintenance as it can lead to rapid

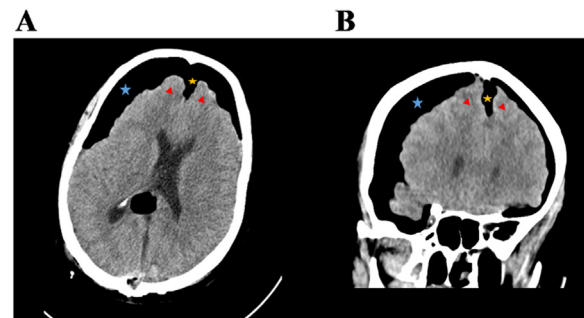


Figure 1 Computed tomographic imaging of the brain in the axial and coronal sections (Panel A and B respectively) demonstrates presence of air (blue star) inside the cranial vault (pneumocephalus) after resection of a pineal meningioma. Possibility of tension pneumocephalus is suggested by the presence of the Mount Fuji radiographic sign in Panel A; the frontal lobes (red triangles) are compressed by the subdural air collection (blue star) with widening of the interhemispheric fissure (gold star), creating a resemblance to the silhouette of Mount Fuji.

expansion of the intracranial gas collection, worsening pneumocephalus severity.

Declaration of Competing Interest

The authors declare no conflicts of interest.

* Corresponding author.

E-mail: khannas@ccf.org (S. Khanna).

References

1. Schirmer CM, Heilman CB, Bhardwaj A. Pneumocephalus: case illustrations and review. *Neurocrit Care*. 2010;13:152–8.
2. Satapathy GC, Dash HH. Tension pneumocephalus after neurosurgery in the supine position. *Br J Anaesth*. 2000;84:115–7.
3. Michel SJ. The Mount Fuji sign. *Radiology*. 2004;232:449–50.